Clinical Oral Investigations (2023) 27:6167–6176
https://doi.org/10.1007/s00784-023-05233-6

RESEARCH

Bilateral arthroscopy of the temporomandibular joint: clinical outcomes and the role of a second intervention—a prospective study

David Faustino Ângelo[1,2,3] · David Sanz[1] · Henrique José Cardoso[1]

Received: 18 May 2023 / Accepted: 21 August 2023 / Published online: 26 August 2023
© The Author(s), under exclusive licence to Springer-Verlag GmbH Germany, part of Springer Nature 2023

Abstract

Objective Evaluate the efficacy of bilateral temporomandibular joint (TMJ) arthroscopy in patients with different categories of severity based on Dimitroulis classification (categories 2–4) and the role of a second TMJ intervention in primary failure.

Methods A 3-year prospective study was designed, including patients submitted to bilateral TMJ arthroscopy. The primary outcome was TMJ pain (VAS, 0–10) and the secondary outcomes were the maximum mouth opening (MMO) and masticatory myalgia degree (0–3). In cases of symptomatic relapse, a second TMJ intervention was performed (TMJ arthrocentesis or TMJ open surgery).

Results Eighty patients (93.4% women) were enrolled, with a mean age of 32.40 ± 11.41 years. With an average follow-up of 523.7 days (34–1606), a statistically significant improvement in TMJ pain, MMO, and myalgia degree was observed ($P < 0.0001$). The overall successful outcome of one-single bilateral arthroscopy was ~ 69%. Twenty-two patients relapsed: (1) arthralgia ($n = 15$, 68.18%); (2) arthralgia + myalgia ($n = 4$, 18.18%); (3) dislocated disc without reduction (DDwoR) ($n = 2$, 9.09%); (4) DDwoR + osteoarthrosis (OA) ($n = 1$, 4.55%). Arthralgia was re-managed with TMJ arthrocentesis with local anesthesia ($n = 19$, 86.36%). New DDwoR with or without OA was re-treated with TMJ open surgery ($n = 3$, 13.64%). After the second intervention, the success rate increased to 85%.

Conclusions Bilateral TMJ arthroscopy presented overall benefit in all parameters evaluated.

Clinical relevance This study highlights the importance of TMJ arthroscopy as the first line of treatment for moderate-severe temporomandibular disorders cases contributing to the reduction of TMJ open surgeries.
In cases of arthroscopy unsuccess, TMJ arthrocentesis under local anesthesia was an effective and safe intervention for patients with recurrent TMJ arthralgia.

Keywords Temporomandibular joint disorders · Arthroscopy · Arthralgia · Myalgia · Pain · Minimally invasive surgical procedures

Introduction

Arthroscopy of the temporomandibular joint (TMJ) has been successfully used for arthrogenous temporomandibular disorders (TMD) [1–12]. It was first introduced by Onishi in 1975, as a pioneering technique to treat painful joints, reducing the number of open joint surgeries [13]. This minimally invasive technique allows observation of the TMJ upper compartment tissues and sometimes the lower compartment. TMJ arthroscopy allows joint lysis and lavage (level 1 arthroscopy) and intra-articular surgical procedures (level 2–3 arthroscopy). The clinical success of this technique varies between 50%-92% in several studies [1–10].

Recent studies updated that TMJ arthroscopy promotes a reduction in pain and inflammatory process, restoring the

✉ David Faustino Ângelo
david.angelo@ipface.pt

1 Instituto Português da Face, Rua Tomás Ribeiro, nº71, 5º andar, 1150-227 Lisboa, Portugal

2 Centre for Rapid and Sustainable Product Development, Polytechnic Institute of Leiria, 2430-028 Marinha Grande, Portugal

3 Faculdade de Medicina, Universidade de Lisboa, Avenida Professor Egas Moniz, 1649-028 Lisboa, Portugal

mandibular function with low morbidity [12, 14–16]. TMJ arthroscopy seems to be also long-term effective for relieving TMJ symptoms [11]. However, TMJ arthroscopy is not always successful, and for relapsed patients, it is still debatable which procedure to perform.

The TMJ arthroscopy surgical indication can be based on TMD severity, and some authors have studied TMJ arthroscopy through different Wilkes' classifications [17–19]. However, the authors in this study, used the Dimitroulis' classification published in 2013. This more recent classification introduced a broader spectrum of TMD subtypes and suggests an indication of the type of treatment to be performed [20]. This prospective study included only patients submitted to bilateral TMJ arthroscopy with different Dimitroulis stages and also described the need for complementary treatments in cases of TMJ arthroscopy failure.

Material and methods

Study design

A prospective clinical study was conducted at *Instituto Português da Face* (IPF) in Lisbon, Portugal, from January 2, 2019, to June 30, 2022. The *Instituto Português da Face* ethics committee approved this investigation (PT/IPFace//RCT/02230/06). All the patients gave their written informed consent to the current legislation and the guidelines of the Declaration of Helsinki.

The study encompassed patients referred for a TMJ surgeon after the failure of conservative treatment for at least three months (pharmacological therapy, occlusal splints, and physiotherapy). The inclusion criteria were: (1) age > 18 years; (2) conservative treatment without any improvement for at least three months; (3) clinical and imaging diagnosis of bilateral arthrogenous disorder (internal derangements, osteoarthrosis, arthralgia); (4) magnetic resonance imaging (MRI) and/or computed tomography (CT) corroborating arthrogenous TMD (5) Dimitroulis classification between 2 and 4, where the imagiology shows that the most components of the TMJ were salvageable. The exclusion criteria were: (1) a history of facial trauma or previous TMJ surgery; (2) severe medical problems or impaired cognitive capacity; (3) pregnant or breastfeeding women. The patient complaints and medical records were registered in EUROTMJ DATABASE (https://eurotmj.org). The final arthrogenous diagnosis was confirmed and assessed through MRI (disc position, disc perforation) and/or CT (osteoarthrosis, osteophytes, and condylar resorption).

All the outcomes were assessed one week before the bilateral TMJ arthroscopy (T0) and after the procedure (T1) (one month, three months, six months, one year, and every year since). One month was the minimum follow-up time.

All patients were observed by the same TMJ surgeon (David Ângelo, PhD, MD.).

The primary clinical outcome was TMJ pain (arthralgia), accessed through Visual Analog Scale (VAS, 0–10, with 0 being no pain and 10 having maximum insupportable pain). In addition, arthralgia was reported if verified: 1) history of pain on the TMJ area and 2) pain on palpation of the lateral pole *or* around the lateral pole or pain on maximum unassisted or assisted opening, right or left lateral movements, or protrusive movements.

The secondary outcomes were the maximum mouth opening (MMO, mm) and facial myalgia degree. MMO was measured using a certified ruler between the incisor's teeth. Myalgia was diagnosed according to a clinical history positive for: 1) in the past 30 days, pain in the jaw, in front of the ear, or the ear with examiner confirmation of pain location masticatory muscles and 2) pain modified with jaw movement, function or parafunction and a positive clinical evaluation for palpation pressure (5 s/1 kg pressure) in masseter and temporalis muscles as defined in DC/TMD [21]. Myalgia was graded accordingly with pain intensity in each muscle: 0 = No Pain/Pressure Only; 1 = Mild Pain; 2 = Moderate Pain; 3 = Severe Pain [22].

The clinical severity was classified accordingly to Dimitroulis classification: category 2-TMJ minor changes; 3-TMJ moderate changes; 4-TMJ severe changes [20]. All patients classified with Dimitroulis 4 were informed that they had an indication for TMJ open surgery but opted for minimally invasive treatment.

To define the success criteria, authors used two categories to classify the TMJ pain: good if VAS ≤ 2 and failure if VAS > 2. In MMO, the authors defined the cut-off of success for MMO ≥ 35 mm (good ≥ 35 mm and acceptable between ≥ 30 mm and < 35 mm) and failure for MMO < 30 mm in the postoperative evaluation. The outcomes were graded together as good, acceptable, and failure according to Table 1 as described by Eriksson, et al.

Table 1 Criteria for classification of three postoperative outcomes

Criteria for classification of three postoperative outcomes	
Good	No pain or only mild pain level (VAS ≤ 2 on a 0–10 scale) and MMO ≥ 35 mm
Acceptable	No pain or only mild pain level (VAS ≤ 2 on a 0–10 scale) and MMO ≥ 30 mm and < 35 mm
Failure	Pain constantly or moderate (VAS > 2 on a 0–10 scale) and/or MMO < 30 mm

[23]. With the initial diagnosis of TMD, the patients were also instructed to answer the Fonseca Anamnestic Index (FAI). The survey was applied in Portuguese, already validated in the literature [24]. The final score obtained was interpreted in four possible categories of severity: no TMD (0 < FAI < 15 points), mild TMD (20 < FAI < 40 points), moderate TMD (45 < FAI < 65 points), and severe TMD (70 < FAI < 100 points) [25].

Treatment protocol

The TMJ arthroscopy was performed with a 1.9-mm arthroscope, including a video system (Stryker, San Jose, CA, USA), with a 2.8-mm outer protective cannula. Additional equipment has been previously described [16]. For TMJ arthroscopy level 1, the authors used the classic puncture based on the Holmlund–Hellsing (H–H) line with an entry point 10 mm anterior and 2 mm below. The arthroscope was inserted into the superior joint space. A second puncture with a 21G needle was performed 30 mm anterior and 7 mm below the H–H line to wash the joint with 250–300 ml Ringer solution. For level 2 TMJ arthroscopy, the second puncture was substituted by a 2.8-mm outer protective cannula with a sharp trocar until the joint was reached. The 2.8-mm cannula was used for an instrumental passageway for (1) a ReFlex Ultra 45 Plasma Wand system for intra-articular coblation and/or (2) intrasynovial medication through a 22G long spinal needle. For level 3 TMJ arthroscopy, a 3/0 PDS was used to suture the disc. During TMJ arthroscopy, the level of intervention was decided according to the following criteria: Level 1- if the percentage of roofing was 100% and no synovitis; Level 2—if the percentage of roofing > 50% and/or synovitis; Level 3 – if after completion of level 2, it remains a percentage of roofing > 50%. A supplemental injection with hyaluronic acid (1.5 ml) was performed. Antibiotic protocol (amoxicillin/clavulanic acid or clarithromycin) and non-steroidal anti-inflammatory drugs (ibuprofen) were routinely prescribed following surgery.

All patients with myalgia grades 2 and 3 were treated in the masticatory muscles (equally distributed in the right and left temporal and master muscles) before surgery with 155U or 195U of Incobotulinum toxin A (Xeomin® - Merz), respectively. This treatment was performed 15 days before TMJ arthroscopy [26].

After surgery, patients were instructed to follow a soft diet for three days and to realize five and three physiotherapy and speech sessions, starting three-five days after the intervention.

Statistical analysis

Data were analyzed using GraphPad Prism (v9.0.0) and IBM SPSS (v26) software. The variables were expressed as the mean (± standard deviation (SD)). Student's paired *t*-test was used for variables with normal distribution and Signed Ranks Test for variables without normal distribution. In addition, the severity was analyzed through the Mann–Whitney test for numerical variables and the Chi-square test for categorical variables. $P < 0.05$ was considered statistically significant.

Results

In the present study, 80 patients (74 female and 6 male) were enrolled, representing 160 operated joints. Their mean age was 32.40 ± 11.41 years. The mean follow-up period was 523.7 ± 468.2 (34–1606) days. The arthrogenous diagnosis more common were: (1) Dislocated disc with reduction (DDwR) with arthralgia (30.00%, $n = 48$ joints); (2) Dislocated disc without reduction (DDwoR) with arthralgia (18.75%; $n = 30$ joints); (3) DDwR (10.0%; $n = 16$ joints); (4) DDwoR with osteoarthrosis (OA) and arthralgia (10.00%, $n = 16$ joints) (Table 2). 74 (92.5%) patients presented concomitant masticatory myalgia: level I—9 (11.25%); level II—18 (22.5%); level III—47 (58.75%) (Table 2). The complaints' severity and medical diagnosis were evaluated through clinical history and examination, complemented by FAI and Dimitroulis classification. The FAI divided the patients into mild pathology—13 (16.25%), moderate pathology—25 (31.25%), and severe pathology—42 (52.5%). For Dimitroulis classification, 33 (41.25%) patients were included in Category 2 (TMJ minor changes), 26 (32.5%) in Category 3 (TMJ moderate changes), and 21 (26.25%) patients in Category 4 (TMJ severe changes) (Table 2). A statistically significant reduction was observed in the primary outcome, TMJ pain, from 4.63 ± 3.14 preoperatively (mean ± SD) to 0.38 ± 1.12 (mean ± SD) postoperatively ($p < 0.0001$, Fig. 1a). The percentage of the patients that showed a good outcome reducing pain was 86.25% (Fig. 1b). 11 patients (13.75%) was classified as failure (pain level > 2; VAS 0–10) (Fig. 1b). An MMO improvement from 33.50 ± 8.79 preoperatively to 40.06 ± 5.02 postoperatively was observed ($p < 0.0001$; Fig. 2a). Preoperatively, 27 (33.75%) patients had MMO < 30 mm, 22 patients (27.5%) with MMO between 30–34 mm and 31 (38.75%) patients with MMO ≥ 35 mm. Postoperatively, 74 patients (92.5%) had MMO ≥ 35 mm. 2 patients (2.5%) failed to open more than 30 mm after TMJ arthroscopy (Fig. 2b). A significative reduction of myalgia degree was observed from mean ± SD 2.29 ± 1.02 preoperatively compared with 0.37 ± 0.75 postoperatively ($p < 0.0001$; Fig. 3a). Moreover, 85% of patients had no or low grade of MT (0–1) postoperatively (Fig. 3c).

Table 2 Patients characteristics

Number of patients	80	
Sex		Number of patients (%)
	Female	74 (92.5%)
	Male	6 (7.5%)
Age Mean (mean ± SD)	32.40 ± 11.41	
Follow-up period (days)	523.7 ± 485.21 (34–1606 days)	
		Number of patients (%)
	< 60 days	10 (12.5%)
	60–365 days	31 (38.75%)
	365- 730 days	15 (18.75%)
	> 730 days	24 (30.00%)
Number of joints treated	160	
Preoperative Arthrogenous Diagnosis		Number of joints (%)
	DDwR + Arthralgia	48 (30.00%)
	DDwoR + Arthralgia	30 (18.75%)
	DDwR	16 (10.00%)
	DDwoR + OA + Arthralgia	16 (10.00%)
	Arthralgia	9 (5.63%)
	DDwoR	8 (5.00%)
	DDwR + OA + Arthralgia	7 (4.38%)
	DDwOR + OA	7 (4.38%)
	Condyle Luxation	2 (1.25%)
	DDwoR + OA + Osteophytes	2 (1.25%)
	Disc Perforation + Arthralgia	2 (1.25%)
	OA + Condyle Luxation + Arthralgia	2 (1.25%)
	OA + Arthralgia	2 (1.25%)
	DDwoR + Condylar Resorption + Arthralgia	1 (0.63%)
	DDwoR + OA + Condylar Resorption	1 (0.63%)
	DDwoR + OA + Disc Perforation	1 (0.63%)
	DDwoR + OA + Osteophytes	1 (0.63%)
	DDwR + Condylar Resorption + Arthralgia	1 (0.63%)
	DDwR + OA + Arthralgia + Disc Perforation	1 (0.63%)
	DDwR + Osteophtyes	1 (0.63%)
	Disc Perforation + OA + Arthralgia	1 (0.63%)
	OA	1 (0.63%)
Preoperative Myogenous Diagnosis		Number of patients (%)
	Myalgia	74 (92.5%)
	I	9 (11.25%)
	II	18 (22.5%)
	III	47 (58.75%)
Fonseca Anamnestic Index (FAI)		Number of patients (%)
	Mild	13 (16.25%)
	Moderate	25 (31.25%)
	Severe	42 (52.5%)
Dimitroulis Classification		Number of patients (%)
	2 -TMJ minor changes	33 (41.25%)
	3 - TMJ moderate changes	26 (32.5%)
	4 -TMJ severe changes	21 (26.25%)

Table 2 (continued)

Arthroscopy Level	Number of joints (%)
I	45 (28.125%)
II	106 (66.250%)
III	9 (5.625%)

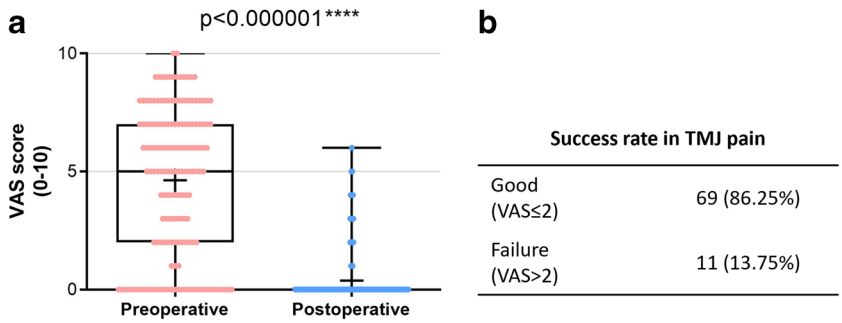

Fig. 1 Statistical test results (**a**) and success rate (**b**) for VAS comparing preoperative and postoperative VAS results. The horizontal line of the box- and whisker graph displays the median, the box edges show the 25th and 75th percentiles and the whiskers show the most minor and highest value within 1.5 box lengths from the box. ****$p < 0.0001$ when compared to preoperative VAS results

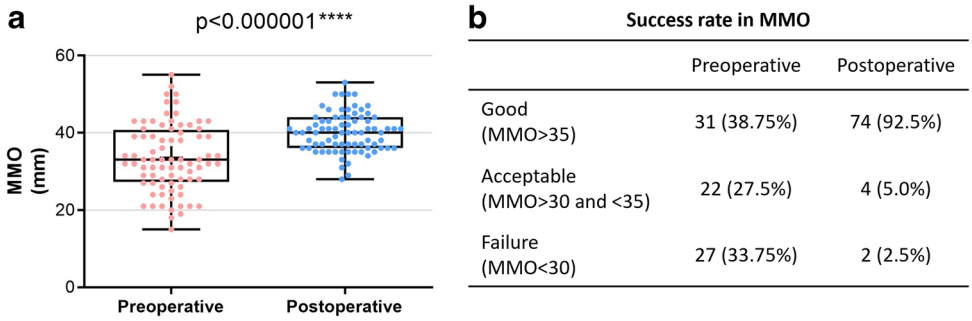

Fig. 2 Statistical test results (**a**) and success rate (**b**) for MMO comparing preoperative and postoperative MMO results. The horizontal line of the box- and whisker graph displays the median, the box edges show the 25th and 75th percentiles and the whiskers show the most minor and highest values. All points are represented with circles. **** $p < 0.0001$ when compared to preoperative MMO results

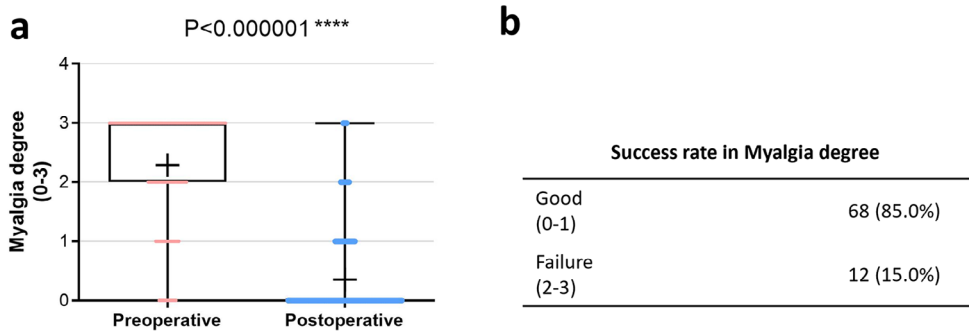

Fig. 3 Statistical test results (**a**) and success rate (**b**) for myalgia degree comparing preoperative and postoperative myalgia degree results. The horizontal line of the box- and whisker graph displays the median, the box edges show the 25th and 75th percentiles and the whiskers show the most minor and highest value within 1.5 box lengths from the box. **** $p < 0.0001$ when compared to preoperative myalgia degree results

Using the classification of Table 1, one-single TMJ arthroscopy was considered successful in 55 patients (68.75%),and failed in 25 patients (31.25%) (Table 3). Considering the failure cases, 5 patients (7.14%) presented bilateral symptoms.

Of the 80 patients, 22 (27.5%, Fig. 4a) relapsed and were diagnosed postoperatively with: (1) arthralgia ($n=15$, 68.18%); (2) arthralgia + myalgia ($n=4$, 18.18%); (3) DDwoR ($n=2$, 9.09%) (4) DDwoR + OA ($n=1$, 4.55%) (Fig. 4b). Arthralgia and arthralgia + myalgia were managed with TMJ arthrocentesis ($n=19$, 86.36%, Fig. 4b). While new DDwoR with or without OA was treated with open surgery (discopexy with Mitek anchor) ($n=3$, 13.64%, Fig. 4b). After the second intervention success rate increased to 85% ($n=68$), and failures reduced to 15% ($n=12$).

VAS pain scores, MMO, and the success rate were also evaluated regarding the severity of the disease using the FAI and Dimitroulis classification (Tables 4 and 5). There were no differences in the parameters analyzed compared to the Dimitroulis Classification (Tables 4 and 5). No irreversible surgical complications were observed in all patients.

Table 3 The success rate of TMJ arthroscopy

Success rate		
	One single TMJ arthroscopy	One single TMJ arthroscopy + Second TMJ intervention
Good—Acceptable	55 (68.75%)	68 (85.00%)
Failure	25 (31.25%)	12 (15%)

Discussion

This prospective study showed that TMJ arthroscopy is a successful procedure in cases of arthrogenous TMD. At the end of the study, the patients submitted to bilateral TMJ arthroscopy had reduced pain and increased MMO. These outcomes enhance the benefit of TMJ arthroscopic treatment and parallel co-interventions (botulinum toxin, physiotherapy) for myalgia control.

The overall success of the single bilateral arthroscopy in our patients was 69% (~91% for at least one joint). Different authors have studied the effectiveness of TMJ arthroscopy. The success rate varies between 50%-92% for different outcomes [1–10]. Murakami, et al. [11, 27], in two long-term studies of five and ten years, reported an 84–90% overall success rate, showing that this procedure is stable in long-term results. The discrepancy of values obtained in the literature may be related to several factors: 1) outcomes measured; 2) type of surgery; 3) stage of disease; 4) sample size.

In this study, TMJ pain (arthralgia) was considered the primary outcome. A statistical reduction of pain for a

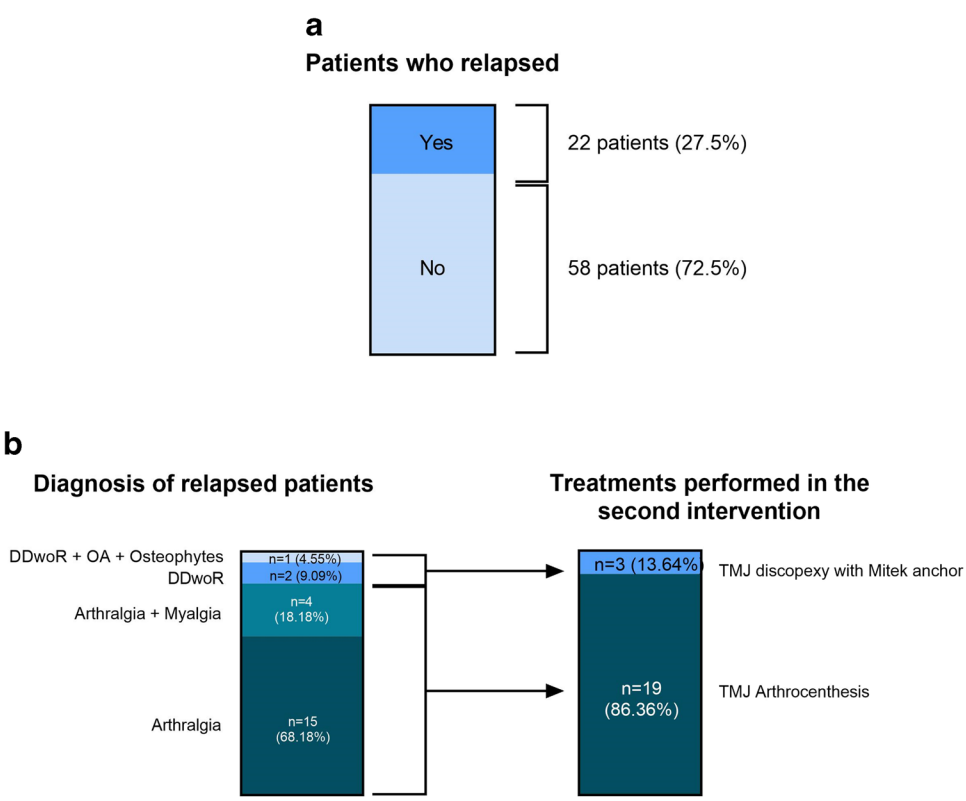

Fig. 4 Analysis of the second intervention after TMJ arthroscopy failure; **a** percentage of patients who relapsed; **b** diagnosis of relapsed patients and treatments performed

Table 4 Pre- and postoperative VAS pain scores, MMO, and success rate and patients undergoing further procedures according to Fonseca Anamnestic Index (FAI)

Outcome of bilateral arthroscopy		VAS pain				MMO				Success rate			Number of patients undergoing further procedures	
FAI	N (%)	Pre-Operative VAS pain, M ± SD	*P*-value	Pos-Operative VAS pain, M ± SD	*P*-value	Pre-Operative MMO, M ± SD	*P*-value	Pos-Operative MMO, M ± SD	*P*-value	Success or Acceptable n, %	Failure, n (%)	*P*-value	N (%)	*P*, value,
Mild -Moderate	38 (47.5%)	3.95 ± 3.15	**0.009****	0.45 ± 1.31	0.767	34.00 ± 8.48	0.639	40.11 ± 5.39	0.860	28 (73.7%)	10 (26.3%)	0.365	8 (21.1%)	0.219
Severe	42 (52.5%)	5.23 ± 3.02		0.31 ± 0.90		33.07 ± 9.09		39.91 ± 4.75		27 (64.3%)	15 (35.7%)		14 (33.3%)	

**$p < 0.01$

Table 5 Pre- and postoperative VAS pain scores, MMO, and success rate and patients undergoing further procedures according to Dimitroulis Classification

Outcome of bilateral arthroscopy		VAS pain				MMO				Success Rate			Number of patients undergoing further procedures	
Dimitroulis	N (%)	Pre-Operative VAS pain, M ± SD	*P*-value	Pos-Operative VAS pain, M ± SD	*P*-value	Pre-Operative MMO, M ± SD	*P*-value	Pos-Operative MMO, M ± SD	*P*-value	Success or Acceptable n, %	Failure, n (%)	*P*-value	N (%)	*P*, value,
2	33 (41.25%)	4.47 ± 3.22	0.333	0.35 ± 1.12	0.293	35.24 ± 8.59	0.126	39.73 ± 5.02	0.768	22 (66.7%)	11 (33.3%)	0.113	10 (27.0%)	0.219
3	26 (32.5%)	5.17 ± 2.85		0.58 ± 1.36		30.78 ± 7.45		39.89 ± 5.58		15 (57.7%)	11 (42.3%)		10 (37.0%)	
4	21 (26.25%)	4.19 ± 3.31		0.17 ± 0.62		33.50 ± 8.79		40.81 ± 4.20		18 (85.7%)	3 (14.3%)		2 (12.5%)	

VAS ≤ 2 was observed in 86% of the patients. These results are according to the literature on pain reduction after TMJ arthroscopy. In a multicenter retrospective study involving 4831 joints, McCain, et al. [10] described a decrease in pain and disability in 92% of patients. Indresano [1] also reported a 73% success rate based on pain score in 64 patients. Other authors also evaluated the success through the mouth opening [2, 5, 28–30]. The success of MMO varies between 78%-89% [2, 5, 28–30]. In our study, 93% of the patients had MMO superior to 35 mm post-TMJ arthroscopy.

Masticatory myalgia is also frequently presented in patients with TMD. In the present study, 90% of the patients showed masticatory myalgia. Preoperative bilateral masticatory muscle myalgia was recently described as a suboptimal surgical outcome indicator [14]. In this study, the authors observed an improvement of 85% in postoperative myalgia degree. This result is essential to demonstrate that the protocol implemented with botulinum toxin was effective in cases of masticatory muscle myalgia. Botulinum toxin injections seem crucial to induce muscular relaxation and decrease the TMJ load.

In the literature, the indication of TMJ arthroscopy is still debatable. Most of the studies used the Wilkes classification to study the severity of the disease. In this study, Dimitroulis's classification was used to indicate TMD severity. In this study, for different Dimitroulis severities, the arthroscopy was equally effective in pain reduction, MMO improvement, success rate, and the number of reinterventions. Bronstein, et al. [31], through Wilkes classification, observed 96% of success for stage II, 83% for stage III, 88% for stage IV, and 63% for stage V. Also, Smolka, et al. [19] reported less success for stages IV and V (71.4% and 75%, respectively) than for stages II and III (80% and 85.7%). However, other studies suggested no correlation between the Wilkes score and clinical outcome [4, 17, 32]. Based on our experience and given the results obtained in this study, TMJ arthroscopy should be seen as the gold standard for moderate-severe cases, and in experienced hands, should be the first technique for arthrogenous disorders. In our experience, different levels of TMJ arthroscopy need to be implemented, taking into account the conditions observed: Level 1- if the percentage of roofing was 100% and no synovitis; Level 2—if the percentage of roofing > 50% and/or synovitis; Level 3 – if after completion of level 2, it remains a percentage of roofing > 50%. However, TMJ arthroscopy seems insufficient for more severe stages of internal derangement with severe degenerative changes, fibrous/bony ankylosis, condyle hyperplasia, condyle fractures, and TMJ tumors – Dimitroulis 5.

In this report, 31% of the patients required postoperative re-intervention: 74.2%—unilateral/ 25,8%—bilateral. 86% performed a TMJ arthrocentesis, and 9% a TMJ open surgery. After the second intervention, the success rate increased to 85%. Based on our experience, a TMJ arthrocentesis under local anesthesia after TMJ arthroscopy failure represents an added value in the resolution of TMJ arthralgia. In cases of new DDwoR, discopexy with Mitek anchor was performed to anchor the disc more definitively. Breik, et al. [33] showed that 77.7% of joints did not require further surgery and pointed out that the rate of progression to open surgery after arthroscopy is more common in the disease's last stages [33]. Some authors have pointed out that a second arthroscopy is an acceptable alternative after arthroscopy failure [12, 34]. In our opinion, a post arthroscopy arthrocentesis under local anesthesia is a very comfortable technique to perform initially and see the results. As mentioned, we obtained satisfactory results with this approach, however further research is needed to help the clinician select which cases are most likely to respond to TMJ arthroscopy and which cases are better for open TMJ surgery. Different risk factors should be studied in depth to understand whether they lead to unsatisfactory outcomes and help the clinician treat the patient in a personalized way. In particular, it has been shown that depression can contribute to the need for further surgery [35].

In this study, no irreversible complications during the arthroscopic procedures were noticed. TMJ arthroscopy is a safe procedure if experienced surgical teams are involved, with the correct arthroscopic armamentarium and the puncture point landmarks being respected [16].

This study had limitations. This study was a single-center study with a small sample size. Further studies with multicenter, large sample size are warranted. Patients with Dimitroulis 5 were not included.

Overall, TMJ arthroscopy should be considered the first line of treatment for moderate-severe cases when the articular disc is salvageable. This study showed that bilateral TMJ arthroscopy is a reliable and effective surgery with high symptom resolution rates. In this study, TMJ arthroscopy's success rate was independent of TMD severity based on FAI and Dimitroulis classification. In cases of TMJ arthroscopy unsuccess associated with arthralgia, TMJ arthrocentesis under local anesthesia can be an effective and safe re-intervention for most patients.

Author contribution DFA: conceptualization, methodology, validation, investigation, resources, writing—original draft preparation, writing—review and editing, supervision, project administration. HJC: conceptualization, methodology, formal analysis, investigation, data curation, writing—original draft preparation, writing—review and editing, project administration. DS: conceptualization, methodology, validation, investigation, resources, writing—review and editing. All authors read and approved the manuscript.

Data availability The data that support the findings of this study are available from the corresponding author [David Ângelo] upon reasonable request.

Declarations

Ethics approval The study was conducted with the ethical principles of the Helsinki Declaration and obtained the consent of the *Instituto Português da Face* ethics committee (PT/IPFace//RCT/02230/06).

Consent to participate All participants received and signed informed consent forms.

Conflict of interest The authors declare no competing interests.

References

1. Indresano AT (1989) Arthroscopic surgery of the temporomandibular joint: report of 64 patients with long-term follow-up. J Oral Maxillofac Surg: Off J Am Assoc Oral Maxillofac Surg 47:439–441. https://doi.org/10.1016/0278-2391(89)90274-7
2. Dimitroulis G (2002) A review of 56 cases of chronic closed lock treated with temporomandibular joint arthroscopy. J Oral Maxillofac Surg: Off J Am Assoc Oral Maxillofac Surg 60:519–524. https://doi.org/10.1053/joms.2002.31848. (discussion 525)
3. Holmlund A, Gynther G, Axelsson S (1994) Efficacy of arthroscopic lysis and lavage in patients with chronic locking of the temporomandibular joint. Int J Oral Maxillofac Surg 23:262–265. https://doi.org/10.1016/S0901-5027(05)80104-3
4. Silva PA, Lopes MT, Freire FS (2015) A prospective study of 138 arthroscopies of the temporomandibular joint. Braz J Otorhinolaryngol 81:352–357. https://doi.org/10.1016/j.bjorl.2014.08.021
5. Machoň V, Levorová J, Hirjak D, Beňo M, Drahoš M, Foltán R (2021) Does arthroscopic lysis and lavage in subjects with Wilkes III internal derangement reduce pain? Oral Maxillofac Surg. https://doi.org/10.1007/s10006-020-00935-7
6. Perrott DH, Alborzi A, Kaban LB, Helms CA (1990) A prospective evaluation of the effectiveness of temporomandibular joint arthroscopy. J Oral Maxillofac Surg 48:1029–1032. https://doi.org/10.1016/0278-2391(90)90283-8
7. Sorel B, Piecuch JF (2000) Long-term evaluation following temporomandibular joint arthroscopy with lysis and lavage. Int J Oral Maxillofac Surg 29:259–263
8. Kurita K, Goss AN, Ogi N, Toyama M (1998) Correlation between preoperative mouth opening and surgical outcome after arthroscopic lysis and lavage in patients with disc displacement without reduction. J Oral Maxillofac Surg 56:1394–1397. https://doi.org/10.1016/S0278-2391(98)90401-3
9. Kondoh T, Dolwick MF, Hamada Y, Seto K (2003) Visually guided irrigation for patients with symptomatic internal derangement of the temporomandibular joint: A preliminary report. Oral Surg Oral Med Oral Pathol Oral Radiol Endodontol 95:544–551. https://doi.org/10.1067/moe.2003.160
10. McCain JP, Sanders B, Koslin MG, Quinn JH, Peters PB, Indresano AT (1992) Temporomandibular joint arthroscopy: a 6-year multicenter retrospective study of 4,831 joints. J Oral Maxillofac Surg: Off J Am Assoc Oral Maxillofac Surg 50:926–930. https://doi.org/10.1016/0278-2391(92)90047-4
11. Murakami K, Segami N, Okamoto M, Yamamura I, Takahashi K, Tsuboi Y (2000) Outcome of arthroscopic surgery for internal derangement of the temporomandibular joint: long-term results covering 10 years. J Craniomaxillofac Surg: Off Publ Eur Assoc Craniomaxillofac Surg 28:264–271. https://doi.org/10.1054/jcms.2000.0162
12. Martin Granizo R, Correa Muñoz DC, Varela Reyes E (2018) Rearthroscopy of the temporomandibular joint: A retrospective study of 600 arthroscopies. J Craniomaxillofac Surg 46:1555–1560. https://doi.org/10.1016/j.jcms.2017.12.007
13. Onishi M (1975) Arthroscopy of the temporomandibular joint (author's transl). Kokubyo Gakkai Zasshi 42:207–213
14. Ulmner M, Weiner CK, Lund B (2020) Predictive factors in temporomandibular joint arthroscopy: a prospective cohort short-term outcome study. Int J Oral Maxillofac Surg 49:614–620. https://doi.org/10.1016/j.ijom.2019.09.002
15. Ângelo DF, Moreira A, Sanz D, São João R (2021) Hearing changes after temporomandibular joint arthroscopy: a prospective study. Int J Oral Maxillofac Surg. https://doi.org/10.1016/j.ijom.2021.02.013
16. Ângelo DF, Araújo RAD, Sanz D (2021) Surgical complications related to temporomandibular joint arthroscopy: a prospective analysis of 39 single-portal versus 43 double-portal procedures. Int J Oral Maxillofac Surg 50:1089–1094. https://doi.org/10.1016/j.ijom.2020.07.020
17. González-García R, Rodríguez-Campo FJ (2011) Arthroscopic lysis and lavage versus operative arthroscopy in the outcome of temporomandibular joint internal derangement: a comparative study based on Wilkes stages. J Oral Maxillofac Surg: Off J Am Assoc Oral Maxillofac Surg 69:2513–2524. https://doi.org/10.1016/j.joms.2011.05.027
18. Ahmed N, Sidebottom A, O'Connor M, Kerr HL (2012) Prospective outcome assessment of the therapeutic benefits of arthroscopy and arthrocentesis of the temporomandibular joint. Br J Oral Maxillofac Surg 50:745–748. https://doi.org/10.1016/j.bjoms.2012.01.004
19. Smolka W, Iizuka T (2005) Arthroscopic lysis and lavage in different stages of internal derangement of the temporomandibular joint: correlation of preoperative staging to arthroscopic findings and treatment outcome. J Oral Maxillofac Surg: Off J Am Assoc Oral Maxillofac Surg 63:471–478. https://doi.org/10.1016/j.joms.2004.07.021
20. Dimitroulis G (2013) A new surgical classification for temporomandibular joint disorders. Int J Oral Maxillofac Surg 42:218–222. https://doi.org/10.1016/j.ijom.2012.11.004
21. Schiffman E, Ohrbach R, Truelove E, Look J, Anderson G, Goulet JP, List T, Svensson P, Gonzalez Y, Lobbezoo F et al (2014) Diagnostic Criteria for Temporomandibular Disorders (DC/TMD) for clinical and research applications. J Oral Facial Pain Headache 28:6–27. https://doi.org/10.11607/jop.1151
22. Goiato MC, Zuim PRJ, Moreno A, Dos Santos DM, da Silva EVF, de Caxias FP, Turcio KHL (2017) Does pain in the masseter and anterior temporal muscles influence maximal bite force? Arch Oral Biol 83:1–6. https://doi.org/10.1016/j.archoralbio.2017.06.029
23 Eriksson L, Westesson PL (2001) Discectomy as an effective treatment for painful temporomandibular joint internal derangement: a 5-year clinical and radiographic follow-up. J Oral Maxillofac Surg: Off J Am Assoc Oral Maxillofac Surg 59:750–758. https://doi.org/10.1053/joms.2001.24288. (discussion 758-759)
24. Campos JA, Carrascosa AC, Bonafé FS, Maroco J (2014) Severity of temporomandibular disorders in women: validity and reliability of the Fonseca Anamnestic Index. Braz Oral Res 28:16–21. https://doi.org/10.1590/s1806-83242013005000026
25. Bevilaqua-Grossi D, Chaves TC, de Oliveira AS, Monteiro-Pedro V (2006) Anamnestic index severity and signs and symptoms of TMD. Cranio: J Craniomandibular Pract 24:112–118. https://doi.org/10.1179/crn.2006.018
26. Ângelo DF, Sanz D, Maffia F, Cardoso HJ (2023) Outcomes of incobotulinumtoxina injection on myalgia and arthralgia in patients undergoing temporomandibular joint arthroscopy: a randomized controlled trial. Toxins 15. https://doi.org/10.3390/toxins15060376

27. Murakami KI, Tsuboi Y, Bessho K, Yokoe Y, Nishida M, Iizuka T (1998) Outcome of arthroscopic surgery to the temporomandibular joint correlates with stage of internal derangement: five-year follow-up study. Br J Oral Maxillofac Surg 36:30–34. https://doi.org/10.1016/s0266-4356(98)90744-6
28. Abboud W, Nadel S, Yarom N, Yahalom R (2016) Arthroscopy of the temporomandibular joint for the treatment of chronic closed lock. Israel Med Assoc J: IMAJ 18:397–400
29. Clark GT, Sanders B, Bertolami CN (1993) Advances in diagnostic and surgical arthroscopy of the temporomandibular joint. Implant Dent 2:136
30. Moses JJ, Sartoris D, Glass R, Tanaka T, Poker I (1989) The effect of arthroscopic surgical lysis and lavage of the superior joint space on TMJ disc position and mobility. J Oral Maxillofac Surg 47:674–678. https://doi.org/10.1016/S0278-2391(89)80004-7
31. Bronstein SL, Merrill RG (1992) J Craniomandib Disord 6:7–16
32. Lockyer JW, Lim CGT (2021) Arthroscopic outcomes in TMJ internal derangement and surgical progression in a single centre in New Zealand. Adv Oral Maxillofac Surg 2:100039. https://doi.org/10.1016/j.adoms.2021.100039
33. Breik O, Devrukhkar V, Dimitroulis G (2016) Temporomandibular joint (TMJ) arthroscopic lysis and lavage: outcomes and rate of progression to open surgery. J Craniomaxillofac Surg: Off Publ Eur Assoc Craniomaxillofac Surg 44:1988–1995. https://doi.org/10.1016/j.jcms.2016.09.017
34 Mancha de la Plata M, Muñoz-Guerra M, Escorial Hernandez V, Martos Diaz P, Gil-DiezUsandizaga JL, Rodriguez-Campo FJ (2008) Unsuccessful temporomandibular joint arthroscopy: is a second arthroscopy an acceptable alternative? J Ora Maxillofac Surg 66:2086–2092. https://doi.org/10.1016/j.joms.2008.06.043
35. Rodrigues ALP, Cardoso HJ, Ângelo DF (2023) Patient experience and satisfaction with different temporomandibular joint treatments: A retrospective study. J Craniomaxillofac Surg: Off Publ Eur Assoc Craniomaxillofac Surg 51:44–51. https://doi.org/10.1016/j.jcms.2023.01.006

Publisher's note Springer Nature remains neutral with regard to jurisdictional claims in published maps and institutional affiliations.

Springer Nature or its licensor (e.g. a society or other partner) holds exclusive rights to this article under a publishing agreement with the author(s) or other rightsholder(s); author self-archiving of the accepted manuscript version of this article is solely governed by the terms of such publishing agreement and applicable law.