Journal of Cranio-Maxillo-Facial Surgery 51 (2023) 659–667

Contents lists available at ScienceDirect

Journal of Cranio-Maxillo-Facial Surgery

journal homepage: www.jcmfs.com

Effectiveness of double-puncture temporomandibular joint arthrocentesis with viscosupplementation in different categories of severity – a prospective study

David Faustino Ângelo [a,b,c,*], David Sanz [a], Henrique José Cardoso [a]

[a] Instituto Português da Face, Lisboa, Portugal
[b] Centre for Rapid and Sustainable Product Development, Polytechnic Institute of Leiria, Portugal
[c] Faculty of Medicine of Lisboa University, Portugal

ARTICLE INFO

Handling Editor: Prof. Emeka Nkenke

Keywords:
Temporomandibular joint disorders
TMJ arthrocentesis
Viscosupplementation
Minimally invasive surgical procedures

ABSTRACT

This 3-year prospective study evaluated the efficacy of temporomandibular joint (TMJ) arthrocentesis with viscosupplementation in different severity stages based on the Dimitroulis classification (categories 2–4 were included). TMJ arthrocentesis was performed under local anaesthesia, and the protocol consisted of a double-puncture technique with lavage of ≥150 cc Ringer Lactate plus viscosupplementation. Incobotulinum toxin A was administered 10–15 days preoperatively in patients with concomitant masticatory myalgia. The primary outcome was TMJ pain, assessed by visual analogue scale (VAS, 0–10), and the secondary outcomes were the maximum mouth opening (MMO, mm) and myalgia degree (0–3). All outcomes were assessed on the intervention day (T0) and after the procedure (T1) (minimum 1 month and then 3 months, 6 months, 1 year and every year since). A total of 108 patients were enrolled (mean age of 43.1 ± 18.9 years); 86 (80%) were women and 22 (20%) were men. Preoperative pain was 4.02 ± 3.12 (mean ± SD), MMO was 38.10 ± 9.56 (mean ± SD) and myalgia degree was 1.80 ± 1.18 (mean ± SD). After an average of 215.4 days (31–1253 days), a statistically significant improvement of pain ($P < 0.0001$), MMO ($P = 0.005$) and myalgia degree ($P < 0.0001$) was observed. The overall successful outcome of TMJ arthrocentesis with viscosupplementation was 76%. The authors observed increased arthrocentesis effectiveness and success rate with viscosupplementation in Dimitroulis category 2 (88.6%) compared to 3–4 (71.4%). An association was found between arthrocentesis with viscosupplementation failure and painful myalgia ($\rho = 0.477$; $P < 0.0001$). Thirteen patients (12%) underwent a second TMJ intervention after finalising the present trial. With a low complication rate, TMJ arthrocentesis with viscosupplementation led to an overall benefit for all the included patients. This study reinforces the important role of minimally invasive TMJ arthrocentesis as a first treatment option, with better results in the early stages compared to more severe stages.

1. Introduction

Temporomandibular joint (TMJ) arthrocentesis with viscosupplementation is a minimally invasive intervention widely used for temporomandibular internal derangements. It is currently accepted as the first line for patient refractory to conservative treatment, including soft diet, pharmacotherapy, occlusal splints and physical therapy (Soni, 2019; Al-Moraissi et al., 2020). It was introduced by Nitzan et al. (1991) as a simple and minimally invasive technique to improve TMJ pain and dysfunction and reestablish normal maximal mouth opening with low morbidity. Occasionally, TMJ arthrocentesis with viscosupplementation is confounded with arthrocentesis or viscosupplementation alone. These are three different approaches associated with a similar concept.

All these arthrocentesis variations are simple, low-risk procedures, mostly performed under local anaesthesia. This technique can be performed in a medical office and easily repeated if necessary. In TMJ arthrocentesis, a mechanical lavage is performed with the objectives of: (1) removing biological mediators of pain and inflammation, namely pro-inflammatory cytokines; (2) breaking down adherences and adhesions; and (3) hypothetically improving the disc position (Emshoff et al., 2000a,b; Emshoff et al., 2000a,b; Şentürk et al., 2021; Castaño-Joaqui et al., 2022). TMJ arthrocentesis is frequently co-adjuvanted with

* Corresponding author. Instituto Português da Face, Rua Tomás Ribeiro, nº71, 5º andar, 1150-227, Lisboa, Portugal.
E-mail address: david.angelo@ipface.pt (D.F. Ângelo).

https://doi.org/10.1016/j.jcms.2023.09.010
Received 18 September 2022; Received in revised form 16 August 2023; Accepted 30 September 2023
Available online 7 October 2023
1010-5182/© 2023 European Association for Cranio-Maxillo-Facial Surgery. Published by Elsevier Ltd. All rights reserved.

additional infiltration of hyaluronic acid (HA), platelet-rich plasma (PRP) or corticosteroids to reduce inflammatory signs and re-establish synovial fluid viscosity (Ungor et al., 2015; Al-Moraissi et al., 2020; Hosgor, 2020, Cömert Kılıç, 2021; Karadayi and Gursoytrak, 2021; Dasukil et al., 2022; Işık et al., 2022; Memiş, 2022). The clinical success of this technique varies between 70 and 90% in several studies (Hosaka et al., 1996; Carvajal and Laskin, 2000; Alpaslan et al., 2003). Some long-term trials have also demonstrated its success in TMJ degenerative disease (Alpaslan et al., 2003; Onder et al., 2009), but this application remains controversial. More recently, some groups have been visco-supplementing the joint without any arthrocentesis lavage, but the results have been unclear (Ferreira et al., 2018; Hosgor, 2020; Sikora et al., 2020, 2022; Chandra et al., 2021).

Initially, TMJ arthrocentesis was proposed for cases of severe limitation of mouth opening, and, as a preliminary TMJ approach before arthroscopy or open surgery (Nitzan et al., 1991; Dimitroulis et al., 1995). However, in recent years, studies have shown therapeutic benefits in various stages of TMJ internal derangement (Nishimura et al., 2001; Hosgor, 2020). Until now, there have been limited studies regarding the clinical evidence for double-puncture TMJ arthrocentesis with viscosupplementation in different severity stages. Wilkes staging is one of the most-used classifications adopted by TMJ surgeons (Wilkes, 1989). However, this classification does not include all types of Temporomandibular Disorders (TMD) or incorporate a treatment indication for each degree of severity. The Dimitroulis classification, introduced more recently, includes a broader spectrum of TMD subtypes and suggests suitable medical treatment for each grade (Dimitroulis, 2013). This prospective study investigated the efficacy of double-puncture TMJ arthrocentesis with viscosupplementation in patients with different severities of TMD based on the Dimitroulis classification.

2. Material and methods

2.1. Study design

This prospective clinical study was conducted from 3 January 2019 to 1 June 2022, after approval by the Instituto Português da Face ethics committee (PT/IPFace//RCT/01218/05). All patients signed the informed consent, in accordance with the Declaration of Helsinki. The study population included patients referred for a TMJ surgical opinion after the failure of non-surgical treatments (anti-inflammatory, muscle relaxant drugs, occlusal splints, and physiotherapy) after at least 3 months. The inclusion criteria for this prospective study were: (1) age >18 years; (2) clinical and imaging diagnosis of unilateral or bilateral intra-articular disorder; (3) magnetic resonance imaging (MRI) assessing the intra-articular derangement; (4) radiological findings that most components of the joint were salvageable; and (5) a Dimitroulis classification between 2 and 4 (Dimitroulis, 2013). The exclusion criteria included: 1) any history of previous TMJ surgical intervention or facial trauma within the last 4 weeks before the study; 2) previous contralateral TMJ surgery; and 3) severe medical problems, mental illness or pregnancy.

The patient's medical records, including medical histories, comorbidities, previous treatments, TMJ complaints and TMJ clinical observations, were registered in EUROTMJ DATABASE (https://eurotmj.org).

2.2. Outcome assessment and criteria for success

All the outcomes were assessed on the day of the intervention (T0) and after the procedure (T1) (1 month, 3 months, 6 months, 1 year and every year since). One month was the minimum follow-up time. The study was completed after 3 years of recruitment. The primary outcome was TMJ pain, assessed by visual analogue score (VAS). Patients were asked to score their average pain levels for the right and left TMJ in the last 6 months using a 0 to 10 scale, with higher scores indicating more severe pain. Arthralgia was diagnosed in accordance with TMD/RDC criteria (Schiffman et al., 2010, Schiffman et al., 2014: 1) positive history of pain in the TMJ area; 2) pain modified with jaw movement, function or parafunction; and 3) pain on palpation of the lateral pole or around the lateral pole, or pain on maximum unassisted or assisted opening, right or left lateral movements, or protrusive movements. The secondary outcomes were the maximum mouth opening (MMO) in mm, and myalgia degree. The authors used a certified ruler between the incisor teeth for the MMO. For myalgia, the authors used the classification defined for TMD/RDC (Schiffman et al., 2010, 2014): 1) pain in the TMJ area in the last 30 days with examiner confirmation in masticatory muscles; and 2) positive clinical evaluation for pain in jaw movement, function or parafunction through palpation pressure (5 s/1 kg pressure) in the masseter and temporalis muscles (Schiffman et al., 2014). The degree of myalgia was defined according to the pain intensity in each muscle: 0 = no pain/pressure only; 1 = mild pain; 2 = moderate pain; and 3 = severe pain (Goiato et al., 2017).

Clinical severity was classified according to the Dimitroulis classification: category 2 – minor TMJ changes; 3 – moderate TMJ changes; and 4 – severe TMJ changes (Dimitroulis, 2013).

To define the criteria for success, the authors used 2 categories to classify the pain: success if VAS≤2, and failure if VAS>2. In MMO, the authors defined the cut-off for success a MMO≥35 mm and that for failure a MMO<35 mm in the postoperative evaluation.

The success rate of the surgery was graded as good, acceptable and failure by Eriksson and Westesson (2001), as described in Table 1.

2.3. Treatment protocol

2.3.1. Botulinum toxin treatment

In patients positive for myalgia degrees 1–2 and 3, 155U and 195U of Incobotulinum toxin A were injected in the masseter and temporal muscles, respectively. The authors used Xeomin® (Merz) in all patients. This treatment was performed 10–15 days before TMJ arthrocentesis.

2.3.2. Double-puncture TMJ arthrocentesis with viscosupplementation under local anaesthesia

Local anaesthesia was accomplished with lidocaine with epinephrine, blocking the auriculotemporal nerve. The first puncture was performed with a careful palpation of the lateral rim of the glenoid fossa. A 5-cc syringe was prepared with 3-cc of Ringer lactate and 1.8 cc of lidocaine with epinephrine (1:80.000). A 21-G needle copulated with the 5 cc syringe was gently introduced in TMJ. After the needle tip had contacted the posterior slope of the eminence of the upper joint compartment, the needle was verticalised to reach the upper compartment. At this point, the surgeon could start to inject the prepared solution. Initially, the authors performed a first validation with a successful pumping action and the inflow and outflow of fluids in the joint. This validation is essential for patient safety. If the surgeon was not able to have a positive pumping , the arthrocentesis was stopped. To perform the second puncture, the authors maintained a maximum joint distention (performing continuous inflow) with the first portal, and the surgeon could feel insufflation/distention in the anterior joint area. After this step, the second portal was easily completed with a 21-G needle in a successful outflow fluid. After an effective circuit was completed, joint washing by intra-articular hydraulic pressure was performed with ≥150 ml of Ringer Lactate solution. After washing, the supplemental

Table 1
Criteria for intervention success.

Good	No pain or only mild pain level (VAS ≤ 2 on a 0–10 scale) and MMO ≥ 35 mm
Acceptable	No pain or only mild pain level (VAS ≤2 on a 0–10 scale) and MMO ≥ 30 mm and < 35 mm
Failure	Pain constantly or moderate (VAS > 2 on a 0–10 scale) and/or MMO < 30 mm

viscosupplementation was performed with 1.5 ml of low molecular weight hyaluronic acid (Suplasyn®, 20 mg/ml) or hyaluronic acid plus platelet-rich plasma (SUPERPRP) in patients with osteoarthrosis (OA). Physiotherapy was performed after the TMJ arthrocentesis with viscosupplementation (4–7 sessions). The patients who presented myalgia after TMJ arthrocentesis had extra physical therapy sessions. In cases of persistent post-treatment myalgia, a second application of botulinum toxin was performed. To reduce possible bias in the results, the date of its application was considered as the last follow-up time.

2.4. Statistical analysis

Data were analysed using the GraphPad Prism (v9) and SPSS (v26) software. The variables were expressed as the mean (± standard deviation (SD)) or %. Student's paired *t*-test was used for variables with normal distribution, and a Wilcoxon Signed-rank test was used for variables without normal distribution. The comparison between Dimitroulis classifications in numerical variables was analysed using a Mann-Whitney test and Student's t-test for non-normal and normal distribution, respectively. The non-parametric Chi-square test ($\chi 2$) or Fisher's exact test were used to determine associations in categorial variables. Association intensity was measured using Cramér's V Coefficient (φc). $P < 0.05$ was considered statistically significant.

3. Results

Of 876 patients, 194 were assessed for eligibility. Of those 194 patients, 78.3% (n = 152) agreed with the treatment plan and were submitted to double-puncture TMJ arthrocentesis with viscosupplementation. During the study, 44 patients did not comply with follow-up visits (drop-out rate = 40.7%) (Table 2). No relevant differences existed between the study and drop-out groups (Table 2). One hundred and eight patients, 86 (80%) female and 22 (20%) male, completed the study (Fig. 1). Their mean age was 43.1 ± 18.9 years. The mean follow-up period was 215.4 ± 244.4.9 days (31–1253 days).

The more common preoperative intra-articular diagnoses were: (1) arthralgia (21.7%, n = 41 joints); (2) dislocated disc with reduction (DDwR) with arthralgia (20.1%; n = 38 joints); and (3) DDwR (18.5%; n = 35 joints) (Table 2). Myalgia was present in 87 patients (80.6%): level 1–15.7% (n = 17); level 2–26.9% (n = 29); level 3–38% (n = 41) (Table 2). When the Dimitroulis classification was used, the severity of TMD was heterogenous: 48.15% (n = 52) patients were in category 2, 37.04% (n = 40) patients were in category 3 and 14.81% (n = 16) were in category 4. Baseline characteristics are summarised in Table 2. A total of 189 joints were submitted to double-puncture TMJ arthrocentesis with viscosupplementation (81 patients with bilateral interventions (85.714%) and 27 patients with unilateral interventions (14.286%)). No surgical complications were observed. After the intervention, TMJ pain was reduced from 4.02 ± 3.12 preoperatively (mean ± SD) to 0.49 ±

Table 2
Patient characteristics.

	Study group		Drop-out group	
Number of patients	108	44		
Sex		Number of patients (%)		Number of patients (%)
	Female	86 (79.6%)		34 (77.3%)
	Male	22 (20.4%)		10 (22.7%)
Age (mean ± SD)	41.1 ± 17.6			37.0 ± 11.2
Number of joints evaluated	216	88		
Joint affected by the intra-articular disorder	189	66		
		Number of joints (%)		Number of joints (%)
	Right side	10 (5.291%)	Right side	7 (10.606%)
	Left side	17 (8.995%)	Left side	8 (12.121%)
	Bilateral	81 (85.714%)	Bilateral	51 (77.273%)
Follow-up period (days)	215.4 ± 244.4.9 (31–1253 days)			
Preoperative intra-articular diagnosis		Number of joints (%)		Number of joints (%)
	Arthralgia	41 (21.7%)	DDwR + arthralgia	19 (28.79%)
	DDwR + arthralgia	38 (20.1%)	Arthralgia	18 (27.27%)
	DDwR	35 (18.5%)	DDwR	17 (25.76%)
	DDwoR + arthralgia	16 (8.5%)	DDwoR + arthralgia	7 (10.61%)
	DDwoR + OA	9 (4.8%)	OA	2 (3.03%)
	OA	8 (4.2%)	OA + arthralgia	2 (3.03%)
	DDwR + OA	7 (4.2%)	DDwR + OA	1 (1.51%)
	DDwR + OA + arthralgia	6 (3.2%)		
	OA + arthralgia	5 (2.6%)		
	DDwoR + OA + arthralgia	5 (2.6%)		
	DDwoR + OA + osteophytes	4 (2.1%)		
	DDwoR	3 (1.6%)		
	DDwR + condylar resorption + arthralgia	3 (1.6%)		
	DDwoR + OA + disc perforation + arthralgia	2 (1.1%)		
	DDwR + condylar resorption	1 (0.5%)		
	DDwR + OA + osteophytes	1 (0.5%)		
	DDwoR + OA + osteophytes + arthralgia	1 (0.5%)		
	DDwoR + OA + disc perforation	1 (0.5%)		
	OA + osteophytes	1 (0.5%)		
	OA + disc perforation + arthralgia	1 (0.5%)		
	Condylar resorption + arthralgia	1 (0.5%)		
Preoperative muscular diagnosis		Number of patients (%)		Number of patients (%)
	Myalgia degree	87 (80.6%)		34 (77.272%)
	1	17 (15.7%)		6 (13.636%)
	2	29 (26.9%)		10 (22.727%)
	3	41 (38.0%)		18 (40.909%)
Dimitroulis classification		Number of patients (%)		Number of patients (%)
	2	52 (48.15%)		25 (56.82%)
	3	40 (37.04%)		14 (31.82%)
	4	16 (14.81%)		5 (11.36%)

1.15 (mean ± SD) postoperatively (P < 0.0001, Fig. 2A). The proportion of the patients who showed a good outcome with reduced pain was 86% (pain level= <2). Fifteen patient procedures (14%) were classified as failures (pain level >2) (Fig. 2B). A statistically significant improvement of MMO was observed after TMJ arthrocentesis with viscosupplementation. The mean MMO increased from 38.10 ± 9.56 preoperatively to 40.93 ± 5.81 postoperatively (P = 0.005; Fig. 3A and B). Approximately 92% of the patients had MMO superior to 35 mm postoperatively. A further 6.48% had an MMO between 30 and 35, and approximately 2% failed to achieve 30 mm of MMO after arthrocentesis (Fig. 3B). A significant reduction in myalgia degree from 1.80 ± 1.18 (mean ± SD) preoperatively to 0.35 ± 0.72 postoperatively was observed (P < 0.0001; Fig. 4A). Of the patients in the study, 84% had no or low degrees of myalgia (0–1) postoperatively (Fig. 4B).

Using the previous classification (Table 1), a single session of double-puncture TMJ arthrocentesis was considered successful in 75.93% of cases (n = 82), acceptable in 3.70% (n = 4) and a failure in 20.37% (n = 22) (Table 3). A analysis was used to assess the association between the success rate of reduced VAS pain score with myalgia postoperatively (Fig. 5). A moderate association between the two variables was verified (φ_c=0.443; P < 0.0001, Fig. 5).

Of the 108 patients who underwent TMJ arthrocentesis, 12% (n = 13) also underwent a second TMJ intervention: (1) TMJ arthrocentesis (n = 10, 77%); (2) TMJ open surgery (discectomy) (n = 2, 15%); or (3) TMJ arthroscopy (n = 1, 8%) (Fig. 6). There was no temporal pattern in need for the new intervention ranging from 40 to 880 days. After the second intervention, the success rate increased to 82.41% (n = 89) (Table 3).

Potential clinical factors affecting the need for a second treatment were identified (Table 4). The presence of other comorbidities and anxiety diagnoses were identified in 59% and 55%, respectively, of these retreated patients (Table 4).

VAS pain scores, MMO and success rate were also evaluated regarding the severity of the disease using the Dimitroulis classification. Postoperative pain was significantly decreased in category 2 compared to 3–4 (P = 0.024; Table 5). The authors observed a significantly higher success rate of arthrocentesis in Dimitroulis category 2 (P = 0.028; Table 5).

An association was used to determine a possible bias in the treatment performed (Table 6). Viscosupplementation with HA or PRP was not associated with postoperative success in VAS, MMO and MT or with success rate and the need for the second surgery (Table 6, Supplementary material).

4. Discussion

This prospective study demonstrates that double-puncture TMJ arthrocentesis with viscosupplementation is an effective procedure in different stages of TMD, but with a significantly higher success rate in category 2 of the Dimitroulis classification. At the end of the study, unilateral and bilateral arthrocentesis with viscosupplementation resulted in a significant reduction of pain and improvement in MMO in all categories.

In recent years, several authors have studied the effectiveness of arthrocentesis (Nitzan et al., 1991; Dimitroulis et al., 1995; Nishimura et al., 2001; Alpaslan et al., 2003; Vos et al., 2014; Gouveia et al., 2015; Leibur et al., 2015; Bas et al., 2019; Hosgor, 2020; Grossmann and Poluha, 2021). However, most of the studies did not evaluate TMD severity (Nitzan et al., 1991; Dimitroulis et al., 1995; Nishimura et al., 2001; Leibur et al., 2015; Bas et al., 2019; Hosgor, 2020). In the few previous studies that discriminated the severity, Wilkes classification was used, but exclusively in stages II-III and IV (Leibur et al., 2015; Ungor et al., 2015). Our study used the Dimitroulis classification (Dimitroulis, 2013). Most cases were category 2 (~48%), corresponding to 'minor TMJ changes' with an indication for arthrocentesis. A further 37% of the patients were classified as category 3 ('moderate TMJ changes') with an indication for arthroscopy or arthroplasty, and ~15% as category 4, referring to 'severe TMJ changes', with an indication for TMJ arthroplasty/discectomy. Accordingly to our results, arthrocentesis showed better results in decreasing pain in level 2 patients compared to level 3 and 4 patients. The success rate was also significantly higher in Dimitroulis 2 patients, although it did not significantly affect the MMO improvement or the need for a second surgical procedure. These results agreed with the Dimitroulis classification, which indicates that

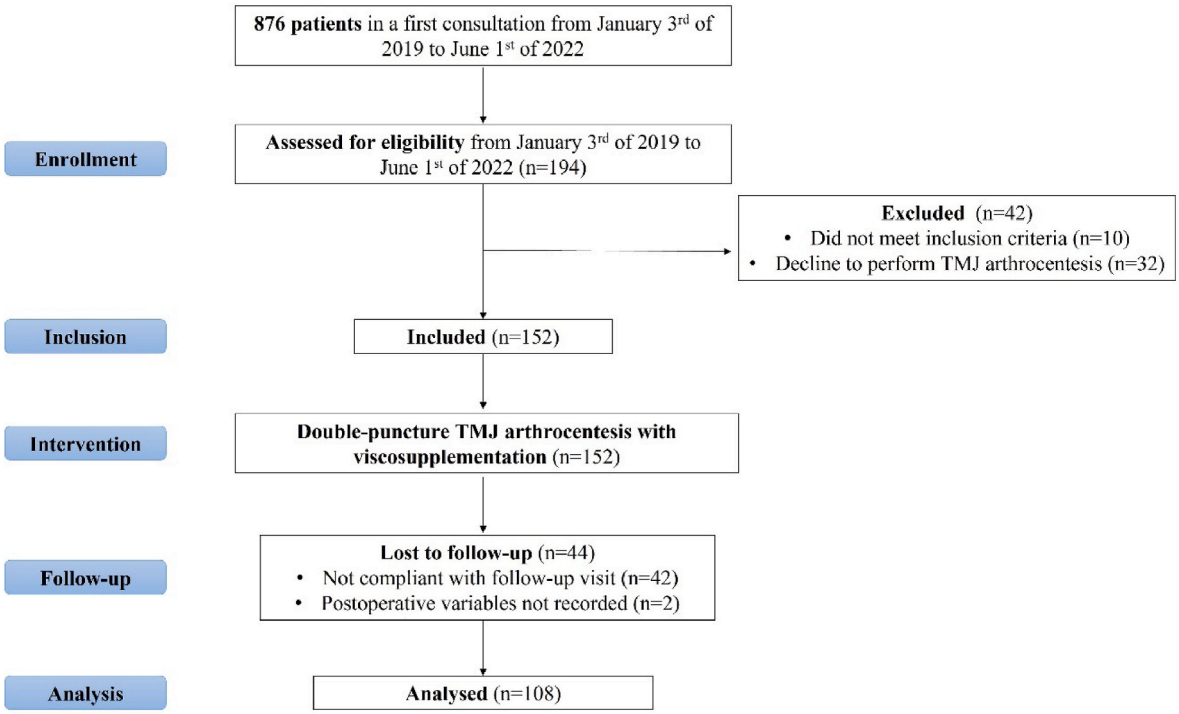

Fig. 1. CONSORT-flow chart diagram reporting of participant enrolment. TMJ - temporomandibular joint.

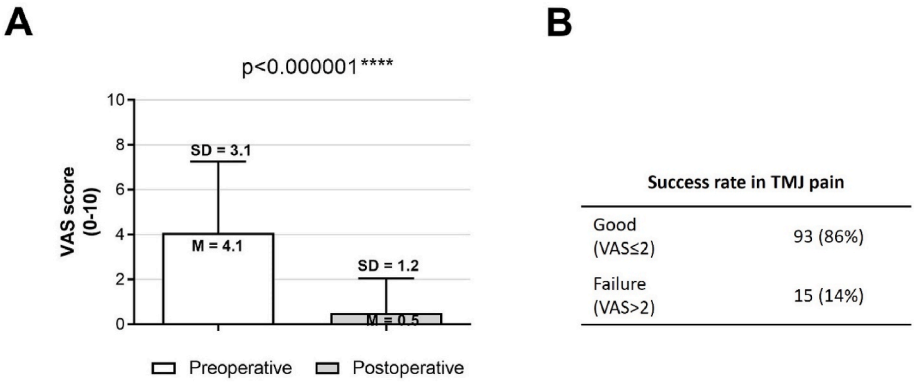

Fig. 2. Statistical test results (A) and success rate (B) for VAS comparing preoperative and postoperative results. Error bars indicate mean (M) ± standard deviation (SD) (n = 108); ****p < 0.0001 when compared to preoperative VAS results.

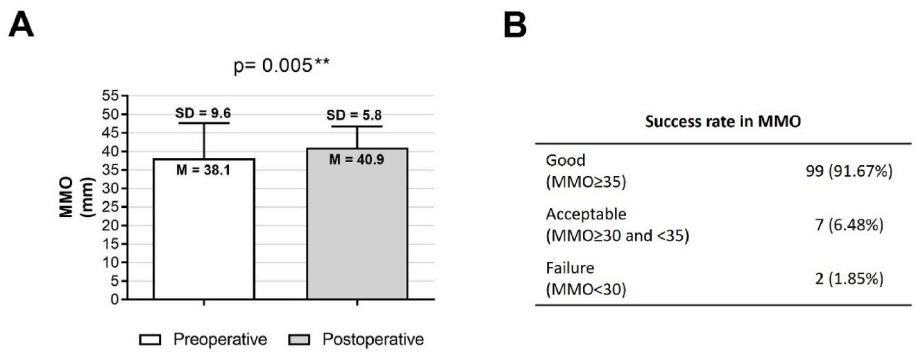

Fig. 3. Statistical test results (A) and success rate (B) for MMO comparing preoperative and postoperative results. Error bars indicate mean (M) ± standard deviation (SD) (n = 108); *p < 0.05 when compared to preoperative MMO results.

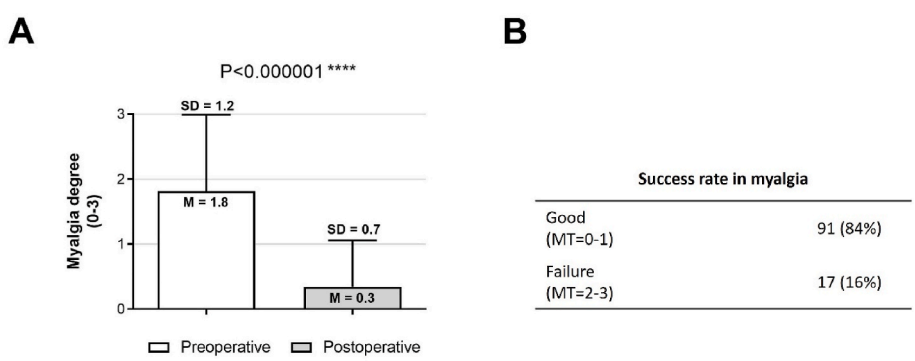

Fig. 4. Statistical test results (A) and success rate (B) for myalgia degree comparing preoperative and postoperative results. Error bars indicate mean (M) ± standard deviation (SD) (n = 108); ****p < 0.0001 when compared to preoperative myalgia degree results.

arthrocentesis should indeed be used in cases with early severity. All patients with Dimitroulis 3-4 were informed that they would have clinical indications for other surgical techniques (TMJ arthroscopy or open surgery) and the possibility of recurrence when opting for arthrocentesis. Even so, patients decided on a less invasive procedure, avoiding general anaesthesia.

Interestingly, Ungor et al. (2015) showed that patients in the Wilkes III group had greater improvement in mandibular movement and pain than patients in the Wilkes II group. However, these results are mostly due to higher preoperative pain levels and reduced MMO in the Wilkes III group compared to the Wilkes II group. In our data, the preoperative outcomes were more homogenous in the different categories.

An overall statistically significant reduction in pain was observed from 4.02 ± 3.12 to 0.49 ± 1.15 with 86% of the patients presenting no pain or residual pain levels (VAS<2, 0–10). These results were in accordance with the literature showing the effectiveness of this treatment in reducing patients' pain levels (Vos et al., 2018; Bas et al., 2019; Hosgor, 2020; Ghoneim et al., 2022). This study did not clarify the possible mechanism to explain this decrease wich is also not fully understood. Still, it is expected that the hydraulic pressure and the fluid lavage with this technique considerably decreased the inflammatory mediators present in the synovial fluid (Emshoff et al., 2000a,b; Emshoff et al., 2000a,b; Grossmann and Poluha, 2021; Bayındır et al., 2022). Given the reduction of pain and the elimination of possible adhesions present in the joint, arthrocentesis has been described as an effective method to increase jaw movement (Wilkes, 1989; Dimitroulis et al., 1995; Hosaka et al., 1996; Bas et al., 2019; Hosgor, 2020). In fact, our study showed a small increase in MMO of 38.10 ± 9.56 preoperatively

Table 3
Success rate of double-puncture TMJ arthrocentesis with viscosupplementation.

Success rate		
	Single arthrocentesis	Single arthrocentesis + second intervention
Good	82 (75.93%)	89 (82.41%)
Acceptable	4 (3.70%)	4 (3.70%)
Failure	22 (20.37%)	15 (13.89%)

to 40.93 ± 5.81 postoperatively. Although other studies have found more significant differences in this parameter, the preoperative MMO values were lower, and those studies included patients who had difficulty opening their mouths (Wilkes, 1989; Dimitroulis et al., 1995; Hosaka et al., 1996; Bas et al., 2019; Hosgor, 2020). In our study, 92% of the patients could open themouth more than 35 mm postoperatively. High levels of muscle tenderness and pain surrounding TMJ are common in TMD. Preoperative masticatory muscle tenderness was recently described as indicative of a suboptimal surgical outcome (Ulmner et al., 2020). In our study, ~81% of the patients presented myalgia. The postoperative evaluation of this parameter can be an important component in determining patients' recovery. After our treatment protocol, we verified a significant improvement in myalgia degree from 1.80 ± 1.18 to 0.35 ± 0.72. The protocol implemented with botulinum toxin as an adjuvant to TMJ arthrocentesis with viscosupplementation may have contributed to the effectiveness of TMJ arthrocentesis, as well as the postoperative physiotherapy sessions. This study was not designed to evaluate co-adjuvant treatments more deeply.

The overall success rate in this study was 76%. This value was in accordance with other studies that obtained a range from 70 to 90% (Hosaka et al., 1996; Carvajal and Laskin, 2000; Alpaslan et al., 2003; Yilmaz et al., 2019). All failure cases were associated with a pain level >2. A moderate association between failure cases and pain patterns associated with myalgia was observed. This association is supported by the fact that most success cases presented with low myalgia scores, while the failure cases presented painful myalgia. Several researchers have studied chronic masticatory myalgia, and it is thought that there may be an important contribution of signalling pathways associated with inflammation and pain in the masticatory muscles, contributing to high levels of pain (Meng et al., 2016; Louca Jounger et al., 2017).

Table 4
Potential clinical factors affecting the need for second surgery.

Clinical Factors	N of patients with second surgery (%)
Other comorbidities	9 (59%)
Arrythmia	3 (27%)
Fibromyalgia	2 (18%)
Hypertension	2 (18%)
Osteoporosis	1 (9%)
Crohn's disease	1 (9%)
Gastroesophageal reflux disease	1 (9%)
Depression	1 (9%)
Upper respiratory tract infection	1 (9%)
Anxiety diagnosis	6 (55%)

In addition, we observed how many patients a second surgical intervention was necessary. Thirteen patients (12%) required a new intervention: TMJ arthrocentesis (n = 10, 77%), TMJ open surgery – discectomy (n = 2, 15%) or TMJ arthroscopy (n = 1, 8%). After a second procedure, the success rate increased to 82%. Some authors have pointed out that performing an arthrocentesis sequence may be beneficial to improve patient outcomes (Guarda-Nardini et al., 2021). Still, we decided to perform a new procedure only in failure cases.

We also tried to verify some determinants that may be associated with the need for a new intervention. Interestingly, we found that 59% of the patients who need a further intervention had concomitant diseases, including fibromyalgia, depression and osteoporosis, which have been shown to have some influence on the severity and perception of

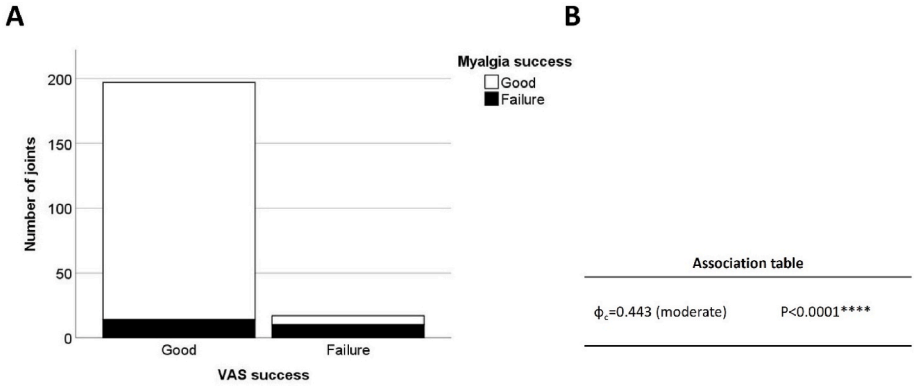

Fig. 5. Association between pain (VAS) and myalgia success rate postoperatively. (A) Association graph between VAS and myalgia success and number of joints. (B) Association test for VAS and myalgia success. φ_c=*Cramér's V;* ****p < 0.0001.

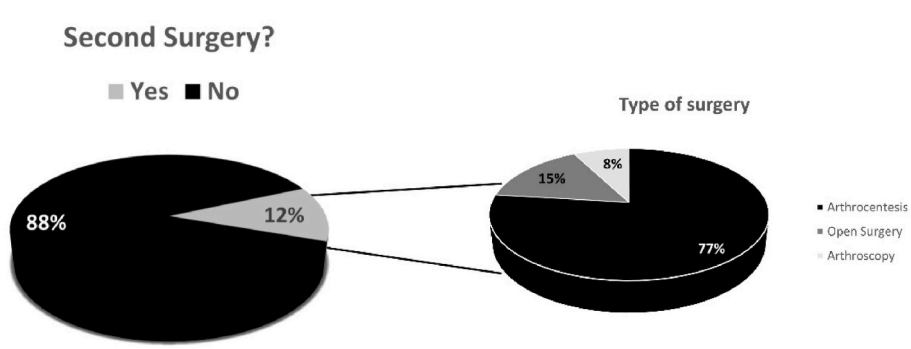

Fig. 6. Analysis of the need for second surgery.

Table 5
Pre- and postoperative VAS pain scores, MMO, and success rate and patients undergoing further procedures according to Dimitroulis classification. M = media; SD = standard deviation.

Outcome of arthrocentesis		VAS pain				MMO			Success rate			Number of patients undergoing further procedures	
Dimitroulis	N (%)	Preoperative VAS pain, M ±SD (Median, [25th, 75th quartiles])	Mann–Whitney *U* test (Z), -value	Postoperative VAS pain, M ±SD (Median, [25th, 75th quartiles])	Mann–Whitney *U* test (Z), P-value	Preoperative MMO, M±SD	Student's t-test (t), P-value	Postoperative MMO, M±SD	Student's t-test (t), P-value	Success or Acceptable n, %	Failure, n (%)	Fisher's exact test, P-value	N (%)	Fisher's exact test, P-value,
2	52 (48.1%)	3.8 ± 3.2 (4.0, [0.0, 7.0])	−0.592, 0.555	0.2 ± 0.9 (0.0 [0.0, 0.0])	**−2,259, 0.024***	38.3.2 ± 8.5	0.154, 0.861	40.7 ± 6.2	0.227, 0.96	46 (88.5%)	6 (11.5%)	**0.028***	4 (9.4%)	0.181
3–4	56 (51.9%)	4.1 ± 3.2 (5.0, [0.3, 7.0])		0.7 ± 1.8 (0.0 [0.0, 0.0])		38.0 ± 10.6		41.2 ± 5.3		40 (71.4%)	16 (28.6%)		9 (17.5%)	

Table 6
Association between treatment variables and postoperatively outcomes. HA – hyaluronic acid; MMO – maximum mouth opening; PRP – platelet-rich plasma; TMJ-temporomandibular joint; X^2 – chi-square test.

Association with treatment variables and outcomes					
Treatment variables	Success in TMJ pain χ^2, p-value	Success in MMO	Success in myalgia	Success rate	Need for a second surgery
TMJ arthrocentesis with HA vs PRP	0.216, 0.642	3.589, 0.166	1.992, 0.158	0.299, 0.861	0.095, 0.758

TMD (Moreno-Fernández et al., 2017; Lee et al., 2021; Kim et al., 2022). In addition, 55% of the patients had been diagnosed with anxiety, an important factor in muscle tension and the perception of pain (Reis et al., 2022). Recently, it was noted that patients with TMD have higher anxiety levels, which can interfere with treatment, reinforcing the need for therapies that consider the various factors of the disorder (Resende et al., 2020). The presence of depression it was also correlated with the need for further TMJ treatment (Rodrigues et al., 2023).

TMJ arthrocentesis also showed positive and stable long-term results (approximately 48 months) regarding increasing the MMO and reducing pain (Spallaccia et al., 2000; Onder et al., 2009; Bergstrand et al., 2019; Castaño-Joaqui et al., 2022). However, the relevant studies included limited numbers of patients (15–40), and it is difficult to draw effective conclusions from them. Carvajal and Laskin, 2000 described 3 of 26 patients as having improved and later relapsed, requiring subsequent surgery. Further research is needed to help clinicians understand which cases arthrocentesis has relapsed and which cases are better to advance to TMJ arthroscopy or open surgery.

Our work reinforces that double-puncture TMJ arthrocentesis with viscosupplementation is a technique that is effective and safe in the early stages of the disease. An important study showed that from an economic perspective, TMJ arthrocentesis was associated with lower costs and presented better health outcomes than conservative treatments (Vos et al., 2018). Moreover, due to its low complication rates, and because it is less invasive and easier to recover from, arthrocentesis can easily be applied in more advanced stages of the disease and in patients who do not wish to be submitted to more invasive treatments.

This study had several limitations 1) it was a single-centre study with a limited sample size; only one surgeon performed all the interventions (DFA). The authors recommend multicentre studies with large sample sizes in the future; 2) this study presented a variable follow-up period (31–1253 days). In the literature, several studies have shown that a variable follow-up can contribute to biased results (von Allmen et al., 2015; Strain et al., 2020). However, this study had no association between follow-up time with failure cases and the need for further intervention; 3) the drop-out rate was 40.7% (44 patients). There were no significant differences in patient characteristics and diagnosis in a drop-out analysis, validating the study group; 4) different co-adjuvant treatments applied, namely viscosupplementation (PRP and HA), botulinum toxin, and physiotherapy. It is important to mention that the application of PRP was exclusive to patients with OA. Other authors have demonstrated the beneficial effects of PRP in OA cases (Karadayi and Gursoytrak, 2021; Asadpour et al., 2022; Işık et al., 2022; Hegab et al., 2023). Recently, Dasukil et al. (2022) demonstrated a slight improvement in joint sounds in the PRP vs HA group after single-puncture arthrocentesis in Wilkes II/III patients. In our study, an association analysis showed that HA or PRP injection was not a determinant in the outcomes measured in this study. The effectiveness of these adjuvant treatments in different TMD diagnoses has not yet been studied in randomised clinical trials, and it is important to clarify that shortly. Additionally, the botulinum toxin injection may have contributed in the long-term to decrease myalgia and arthralgia (Ângelo et al., 2023). Designing a future clinical study demonstrating botulinum toxin

injection's impact on arthrocentesis results is important.

5. Conclusion

Overall, double-puncture TMJ arthrocentesis with viscosupplementation could be considered as the first line of minimally invasive treatment in TMD with a salvageable disc, with higher chance of symptom resolution in Dimitroulis category 2 patients.

Acknowledgements

This research did not receive any specific grant from funding agencies in the public, commercial, or not-for-profit sectors. The authors would like to thank biostatistician Ricardo São João, PhD, (CEAUL-Centro de Estatística e Aplicações, Faculdade de Ciências, Universidade de Lisboa, 1749-016 Lisboa, Portugal) for the statistical review of the paper.

Appendix A. Supplementary data

Supplementary data to this article can be found online at https://doi.org/10.1016/j.jcms.2023.09.010.

References

Al-Moraissi, E.A., Wolford, L.M., Ellis, E., 3rd Neff, A., 2020. The hierarchy of different treatments for arthrogenous temporomandibular disorders: a network meta-analysis of randomized clinical trials. J. Cranio-Maxillo-Fac. Surg. 48, 9–23.
Alpaslan, C., Dolwick, M.F., Heft, M.W., 2003. Five-year retrospective evaluation of temporomandibular joint arthrocentesis. Int. J. Oral Maxillofac. Surg. 32, 263–267.
Ângelo, D.F., Sanz, D., Maffia, F., Cardoso, H.J., 2023. Outcomes of IncobotulinumtoxinA injection on myalgia and arthralgia in patients undergoing temporomandibular joint arthroscopy: a randomized controlled trial. Toxins 15, 376.
Asadpour, N., Shooshtari, Z., Kazemian, M., Gholami, M., Vatanparast, N., Samieirad, S., 2022. Combined platelet-rich plasma and hyaluronic acid can reduce pain in patients undergoing arthrocentesis for temporomandibular joint osteoarthritis. J. Oral Maxillofac. Surg. 80, 1474–1485.
Bas, B., Yuceer, E., Kazan, D., Gurbanov, V., Kutuk, N., 2019. Clinical and intra-operative factors affecting the outcome of arthrocentesis in disc displacement without reduction: a retrospective study. J. Oral Rehabil. 46, 699–703.
Bayındır, Ş., Yılmaz Asan, C., Demirbaş, A.E., Keti, D.B., Kütük, N., 2022. Evaluation of aggrecan and adipokine levels in temporomandibular joint synovial fluid. J. Cranio-Maxillo-Fac. Surg. 50, 432–438.
Bergstrand, S., Ingstad, H.K., Møystad, A., Bjørnland, T., 2019. Long-term effectiveness of arthrocentesis with and without hyaluronic acid injection for treatment of temporomandibular joint osteoarthritis. J. Oral Sci. 61, 82–88.
Carvajal, W.A., Laskin, D.M., 2000. Long-term evaluation of arthrocentesis for the treatment of internal derangements of the temporomandibular joint. J. Oral Maxillofac. Surg. 58, 852–855. ; discussion 856-857.
Castaño-Joaqui, O.G., Maza Muela, C., Casco Zavala, B., Casares García, G., Domínguez Gordillo, A., 2022. Long term oral health related quality of life after TMJ arthrocentesis with hyaluronic acid. A retrospective cohort study. J. Cranio-Maxillo-Fac. Surg. 50, 583–589.
Chandra, L., Goyal, M., Srivastava, D., 2021. Minimally invasive intraarticular platelet rich plasma injection for refractory temporomandibular joint dysfunction syndrome in comparison to arthrocentesis. J Family Med Prim Care 10, 254–258.
Cömert Kılıç, S., 2021. Does glucosamine, chondroitin sulfate, and methylsulfonylmethane supplementation improve the outcome of temporomandibular joint osteoarthritis management with arthrocentesis plus intraarticular hyaluronic acid injection. A randomized clinical trial. J. Cranio-Maxillo-Fac. Surg. 49, 711–718.
Dasukil, S., Arora, G., Boyina, K.K., Jena, A.K., Jose, A., Das, S., 2022. Intra-articular injection of hyaluronic acid versus platelet-rich plasma following single puncture arthrocentesis for the management of internal derangement of TMJ: a double-blinded randomised controlled trial. J. Cranio-Maxillo-Fac. Surg. 50, 825–830.
Dimitroulis, G., 2013. A new surgical classification for temporomandibular joint disorders. Int. J. Oral Maxillofac. Surg. 42, 218–222.
Dimitroulis, G., Dolwick, M.F., Martinez, A., 1995. Temporomandibular joint arthrocentesis and lavage for the treatment of closed lock: a follow-up study. Br. J. Oral Maxillofac. Surg. 33, 23–26. ; discussion 26-27.
Emshoff, R., Puffer, P., Strobl, H., Gassner, R., 2000a. Effect of temporomandibular joint arthrocentesis on synovial fluid mediator level of tumor necrosis factor-alpha: implications for treatment outcome. Int. J. Oral Maxillofac. Surg. 29, 176–182.
Emshoff, R., Rudisch, A., Bösch, R., Gassner, R., 2000b. Effect of arthrocentesis and hydraulic distension on the temporomandibular joint disk position. Oral Surg. Oral Med. Oral Pathol. Oral Radiol. Endod. 89, 271–277.
Eriksson, L., Westesson, P.L., 2001. Discectomy as an effective treatment for painful temporomandibular joint internal derangement: a 5-year clinical and radiographic follow-up. J. Oral Maxillofac. Surg. 59, 750–758.
Ferreira, N., Masterson, D., Lopes de Lima, R., de Souza Moura, B., Oliveira, A.T., Kelly da Silva Fidalgo, T., Carvalho, A.C.P., DosSantos, M.F., Grossmann, E., 2018. Efficacy of viscosupplementation with hyaluronic acid in temporomandibular disorders: a systematic review. J. Cranio-Maxillo-Fac. Surg. 46, 1943–1952.
Ghoneim, N.I., Mansour, N.A., Elmaghraby, S.A., Abdelsameaa, S.E., 2022. Treatment of temporomandibular joint disc displacement using arthrocentesis combined with injectable platelet rich fibrin versus arthrocentesis alone. J. Dent. Sci. 17, 468–475.
Goiato, M.C., Zuim, P.R.J., Moreno, A., Dos Santos, D.M., da Silva, E.V.F., de Caxias, F.P., Turcio, K.H.L., 2017. Does pain in the masseter and anterior temporal muscles influence maximal bite force? Arch. Oral Biol. 83, 1–6.
Gouveia, M.V., Barbalho, J.C., Pereira Júnior, E.D., Nascimento, M.M., Vasconcelos, B.C., 2015. Effectiveness and satisfaction evaluation of patients submitted to TMJ arthrocenthesis: a case series. Braz. Oral Res. 29, 50.
Grossmann, E., Poluha, R.L., 2021. Comparison between TMJ arthrocentesis techniques with different needle positions: a randomized single-blind controlled clinical trial. J. Cranio-Maxillo-Fac. Surg. 49, 368–372.
Guarda-Nardini, L., De Almeida, A.M., Manfredini, D., 2021. Arthrocentesis of the temporomandibular joint: systematic review and clinical implications of research findings. J Oral Facial Pain Headache 35, 17–29.
Hegab, A.F., Hameed, H., Hassaneen, A.M., Hyder, A., 2023. Synergistic effect of platelet rich plasma with hyaluronic acid injection following arthrocentesis to reduce pain and improve function in TMJ osteoarthritis. J. Stomatol. Oral Maxillofac Surg 124, 101340.
Hosaka, H., Murakami, K., Goto, K., Iizuka, T., 1996. Outcome of arthrocentesis for temporomandibular joint with closed lock at 3 years follow-up. Oral Surg. Oral Med. Oral Pathol. Oral Radiol. Endod. 82, 501–504.
Hosgor, H., 2020. Is arthrocentesis plus hyaluronic acid superior to arthrocentesis alone in the treatment of disc displacement without reduction in patients with bruxism? J. Cranio-Maxillo-Fac. Surg. 48, 1023–1027.
Işık, G., Kenç, S., Özveri Koyuncu, B., Günbay, S., Günbay, T., 2022. Injectable platelet-rich fibrin as treatment for temporomandibular joint osteoarthritis: a randomized controlled clinical trial. J. Cranio-Maxillo-Fac. Surg. 50, 576–582.
Karadayi, U., Gursoytrak, B., 2021. Randomised controlled trial of arthrocentesis with or without PRF for internal derangement of the TMJ. J. Cranio-Maxillo-Fac. Surg. 49, 362–367.
Kim, S.Y., Yoo, D.M., Kwon, M.J., Kim, J.H., Kim, J.-H., Byun, S.-H., Park, B., Lee, H.-J., Choi, H.G., 2022. Increased risk of temporomandibular joint disorder in osteoporosis patients: a longitudinal study. Front. Endocrinol. 13, 835923.
Lee, K.C., Wu, Y.T., Chien, W.C., Chung, C.H., Shen, C.H., Chen, L.C., Shieh, Y.S., 2021. Osteoporosis and the risk of temporomandibular disorder in chronic obstructive pulmonary disease. J. Bone Miner. Metabol. 39, 201–211.
Leibur, E., Jagur, O., Voog-Oras, Ü., 2015. Temporomandibular joint arthrocentesis for the treatment of osteoarthritis. Stomatologija 17, 113–117.
Louca Jounger, S., Christidis, N., Svensson, P., List, T., Ernberg, M., 2017. Increased levels of intramuscular cytokines in patients with jaw muscle pain. J. Headache Pain 18, 30.
Memiş, S., 2022. Evaluation of the effects of temporomandibular joint arthrocentesis with hyaluronic acid injection on mandibular condyles using fractal dimension analysis: a retrospective study. J. Cranio-Maxillo-Fac. Surg. 50, 643–650.
Meng, H., Gao, Y., Kang, Y.F., Zhao, Y.P., Yang, G.J., Wang, Y., Cao, Y., Gan, Y.H., Xie, Q. F., 2016. Molecular changes involving MEK3-p38 MAPK activation in chronic masticatory myalgia. J. Dent. Res. 95, 1169–1175.
Moreno-Fernández, A.M., Jiménez-Castellanos, E., Iglesias-Linares, A., Bueso-Madrid, D., Fernández-Rodríguez, A., de Miguel, M., 2017. Fibromyalgia syndrome and temporomandibular disorders with muscular pain. A review. Mod. Rheumatol. 27, 210–216.
Nishimura, M., Segami, N., Kaneyama, K., Suzuki, T., 2001. Prognostic factors in arthrocentesis of the temporomandibular joint: evaluation of 100 patients with internal derangement. J. Oral Maxillofac. Surg. 59, 874–877.
Nitzan, D.W., Dolwick, M.F., Martinez, G.A., 1991. Temporomandibular joint arthrocentesis: a simplified treatment for severe, limited mouth opening. J. Oral Maxillofac. Surg. 49, 1163–1167.
Onder, M.E., Tüz, H.H., Koçyiğit, D., Kişnişci, R.S., 2009. Long-term results of arthrocentesis in degenerative temporomandibular disorders. Oral Surg. Oral Med. Oral Pathol. Oral Radiol. Endod. 107, 1–5.
Reis, P.H.F., Laxe, L.A.C., Lacerda-Santos, R., Münchow, E.A., 2022. Distribution of anxiety and depression among different subtypes of temporomandibular disorder: a systematic review and meta-analysis. J. Oral Rehabil. 49, 754–767.
Resende, C., Rocha, L., Paiva, R.P., Cavalcanti, C.D.S., Almeida, E.O., Roncalli, A.G., Barbosa, G.A.S., 2020. Relationship between anxiety, quality of life, and sociodemographic characteristics and temporomandibular disorder. Oral Surg Oral Med Oral Pathol Oral Radiol 129, 125–132.
Rodrigues, A.L.P., Cardoso, H.J., Ângelo, D.F., 2023. Patient experience and satisfaction with different temporomandibular joint treatments: a retrospective study. J. Cranio-Maxillo-Fac. Surg. 51, 44–51.
Schiffman, E., Ohrbach, R., Truelove, E., Look, J., Anderson, G., Goulet, J.-P., List, T., Svensson, P., Gonzalez, Y., et al., 2014. Diagnostic criteria for temporomandibular disorders (DC/TMD) for clinical and research applications. J. Oral & Facial Pain Headache 28, 6–27.
Schiffman, E.L., Ohrbach, R., Truelove, E.L., Tai, F., Anderson, G.C., Pan, W., Gonzalez, Y.M., John, M.T., Sommers, E., et al., 2010. The Research Diagnostic Criteria for Temporomandibular Disorders. V: methods used to establish and validate revised Axis I diagnostic algorithms. J. Orofac. Pain 24, 63–78.

Şentürk, M.F., Yazıcı, T., Baykul, T., 2021. Evaluation of the effectiveness of different puncture points for second cannula in double puncture arthrocentesis of temporomandibular joint. J. Cranio-Maxillo-Fac. Surg. 49, 1158–1161.
Sikora, M., Czerwińska-Niezabitowska, B., Chęciński, M.A., Sielski, M., Chlubek, D., 2020. Short-term effects of intra-articular hyaluronic acid administration in patients with temporomandibular joint disorders. J. Clin. Med. 9, 1749.
Sikora, M., Sielski, M., Chęciński, M., Nowak, Z., Czerwińska-Niezabitowska, B., Chlubek, D., 2022. Repeated intra-articular administration of platelet-rich plasma (PRP) in temporomandibular disorders: a clinical case series. J. Clin. Med. 11, 4281.
Soni, A., 2019. Arthrocentesis of temporomandibular joint- bridging the gap between non-surgical and surgical treatment. Annals Maxillofacial Surgery 9, 158–167.
Spallaccia, F., Rivaroli, A., Cascone, P., 2000. Temporomandibular joint arthrocentesis: long-term results. Bull Group Int. Rech Sci. Stomatol. Odontol. 42, 31–37.
Strain, T., Wijndaele, K., Sharp, S.J., Dempsey, P.C., Wareham, N., Brage, S., 2020. Impact of follow-up time and analytical approaches to account for reverse causality on the association between physical activity and health outcomes in UK Biobank. Int. J. Epidemiol. 49, 162–172.
Ulmner, M., Weiner, C.K., Lund, B., 2020. Predictive factors in temporomandibular joint arthroscopy: a prospective cohort short-term outcome study. Int. J. Oral Maxillofac. Surg. 49, 614–620.
Ungor, C., Atasoy, K.T., Taskesen, F., Pirpir, C., Yilmaz, O., 2015. Long-term outcome of arthrocentesis plus hyaluronic acid injection in patients with Wilkes stage II and III temporomandibular joint internal derangement. J. Craniofac. Surg. 26, 2104–2108.
von Allmen, R.S., Weiss, S., Tevaearai, H.T., Kuemmerli, C., Tinner, C., Carrel, T.P., Schmidli, J., Dick, F., 2015. Completeness of follow-up determines validity of study findings: results of a prospective repeated measures cohort study. PLoS One 10, e0140817.
Vos, L.M., Huddleston Slater, J.J., Stegenga, B., 2014. Arthrocentesis as initial treatment for temporomandibular joint arthropathy: a randomized controlled trial. J. Cranio-Maxillo-Fac. Surg. 42, 134–139.
Vos, L.M., Stegenga, B., Stant, A.D., Quik, E.H., Huddleston Slater, J.J., 2018. Cost effectiveness of arthrocentesis compared to conservative therapy for arthralgia of the temporomandibular joint: a randomized controlled trial. J Oral Facial Pain Headache 32, 198–207.
Wilkes, C.H., 1989. Internal derangements of the temporomandibular joint. Pathological variations. Arch. Otolaryngol. Head Neck Surg. 115, 469–477.
Yilmaz, O., Candirli, C., Balaban, E., Demirkol, M., 2019. Evaluation of success criteria for temporomandibular joint arthrocentesis. J. Korean Ass. Oral Maxillofac Surg 45, 15–20.